Supplemental materials

Boas FE, Basturk O, Yin Z, Yarmohammadi H, Elkhadragy L, Chiang J, Mohammad IS, Solomon SB. (2026) "Undifferentiated carcinomas in a large animal model of liver cancer." *Animal Model Exp Med*.

Contents

Inoculation technique for Oncopig liver and pancreas 1
Histology of Oncopig liver tumors 2
Tumor 1: Epithelioid cell predominant 3
Tumor 2: Epithelioid cell predominant 8
Tumor 3: Epithelioid cell predominant 11
Tumor 4: Spindle cell predominant 12
Lung metastasis 17
Lymph node metastasis 18

Inoculation technique for Oncopig liver and pancreas

Supplies

- **Ad5CMVCre-eGFP** (University of Iowa Viral Vector Core) should be stored at –80°C, and thawed on ice. To minimize freeze-thaw cycles, we thaw once to aliquot, then thaw the aliquots just prior to inoculation, and then discard any unused portions of an aliquot. Typical concentration is 6×10^{10} pfu/ml, although there is some batch-to-batch variation.
- **Surgifoam** (Ethicon, Absorbable gelatin sponge, 2×6×0.7 cm, Item # 1972).
- **Core biopsy device**. We use 18 G Temno Evolution (Merit Medical, South Jordan, UT).
- **Phosphate buffered saline (PBS)**
- **1 M $CaCl_2$**
- **Oncopigs** (Sus Clinicals) should be > 20 kg at the time of inoculation. For pancreas, pigs ≥ 3 months old are preferred, because fat around the pancreas makes it easier to see on CT.

Technique

1. Mix 10^9 pfu Ad5CMVCre-eGFP (~ 17 µl) with PBS (~ 968 µl), final volume 985 µl. Keep on ice, in a 1.5 ml Eppendorf tube.
2. Get a single 18 G core of the liver or pancreas, using co-axial technique. We generally biopsy liver using ultrasound guidance in the supine position, and pancreas using CT guidance in the prone position. Contrast may be helpful for pancreatic biopsies. Try to get good cores, with minimal blood. Wipe or wash off any excess blood on the core, to reduce transformation of leukocytes.
3. Place the core biopsy in the Eppendorf tube containing virus + PBS.
4. Add $CaCl_2$ to a final concentration of 15 mM (15 µl of 1 M $CaCl_2$). $CaCl_2$ should be added after mixing the virus and core biopsy.
5. Incubate for 20 minutes at room temperature.

6. Take 1/6 sheet of Surgifoam, and rip into several pieces. Put the pieces in a 3 ml polypropylene syringe, and squeeze out the air. Surgifoam retains the virus at the injection site, and creates a receptive microenvironment for tumor growth.
7. Aspirate the virus + PBS + core into a second 3 ml polypropylene syringe, using an 18 G hypodermic needle.
8. Use a 3-way stopcock to mix the Surgifoam syringe, and the virus + PBS + core syringe, by pumping back-and-forth several times.
9. Inject the mixture (virus, core biopsy, Surgifoam) back into the liver or pancreas, through the biopsy needle, which is kept in place after the biopsy. For liver, ultrasound guidance during injection is helpful, to avoid injecting into a fissure, vein, or peritoneum (Hepatic fissures in pigs are difficult to see on CT). Pull back the needle 1 cm during the injection, to inoculate a larger volume of liver or pancreas. Pulling back the needle during injection is also helpful in case the needle is initially in a vein, and it can be pulled back into hepatic/pancreatic parenchyma. Use the inner stylet to push out any remaining material in the needle, before pulling out the needle.
10. After inoculation, pigs should be handled at BSL-2 for 72 hours, and during this time, they should be housed separately from pigs that have not been exposed to virus. After Oncopigs have been exposed to adenovirus, repeat inoculation does not produce more tumors.
11. CT scan and treatment is performed 7 days after inoculation, and CT scan and necropsy is performed 14 days after inoculation.

Histology of Oncopig liver tumors

Oncopig liver tumors were examined 14 days after inoculation. H&E sections reveal undifferentiated carcinomas, characterized by solid sheets of large, loosely cohesive epithelioid to spindle-shaped cells, lacking overt glandular or trabecular differentiation. The neoplastic proliferation is interspersed with a prominent inflammatory infiltrate. Immunohistochemical profiling shows that the tumor cells are strongly vimentin positive, with focal immunoreactivity for cytokeratin AE1/AE3, suggesting epithelial-to-mesenchymal transition. Notably, the tumor cells are immunonegative for Arginase and Iba1, supporting a loss of hepatic differentiation and excluding a primary histiocytic origin. CD31 staining highlights robust tumor-associated angiogenesis within the stroma.

Tumor 1: Epithelioid cell predominant

H&E stain shows numerous large atypical cells.

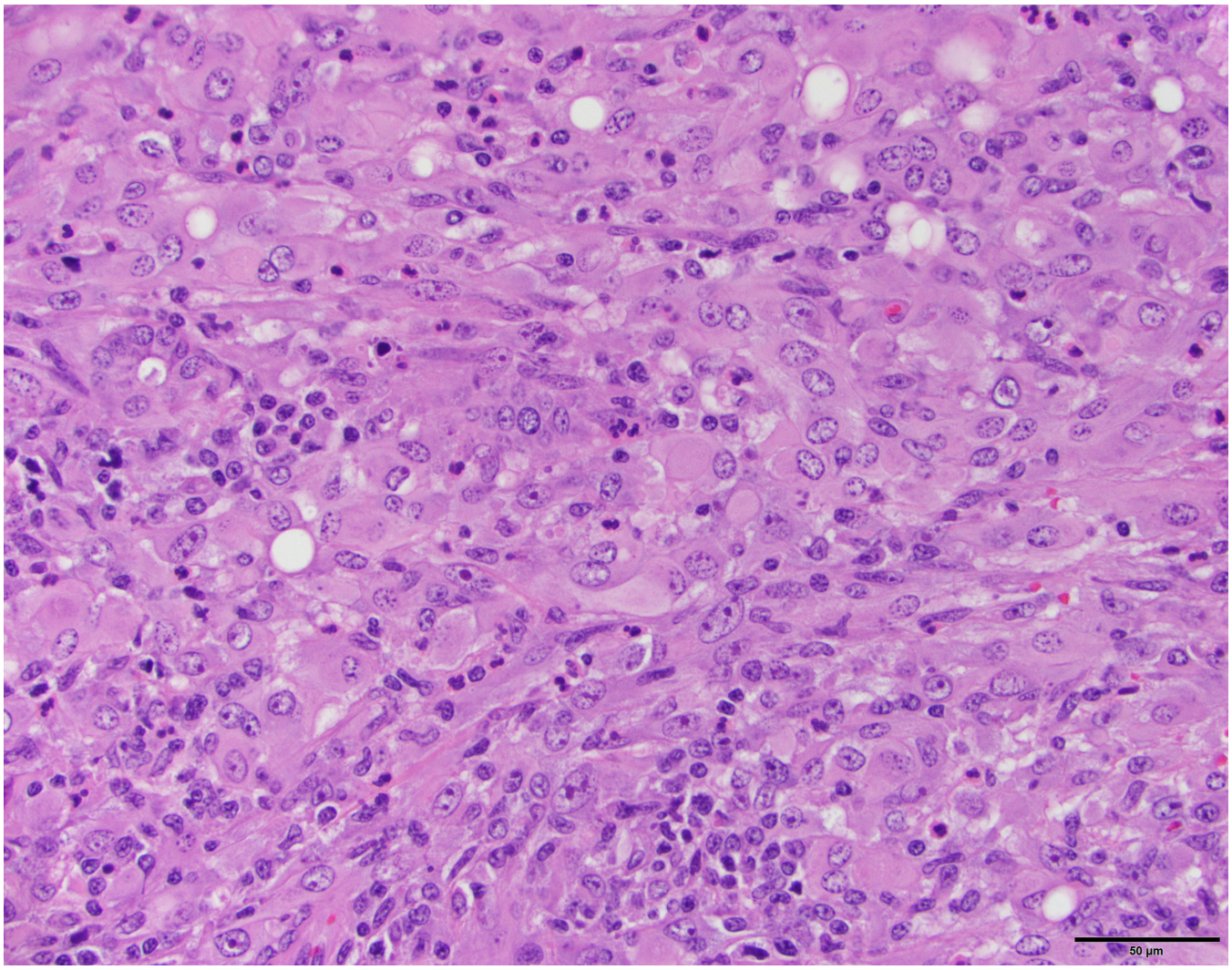

Tumor 1, cytokeratin AE1/AE3 stain shows that the tumor cells are strongly positive.

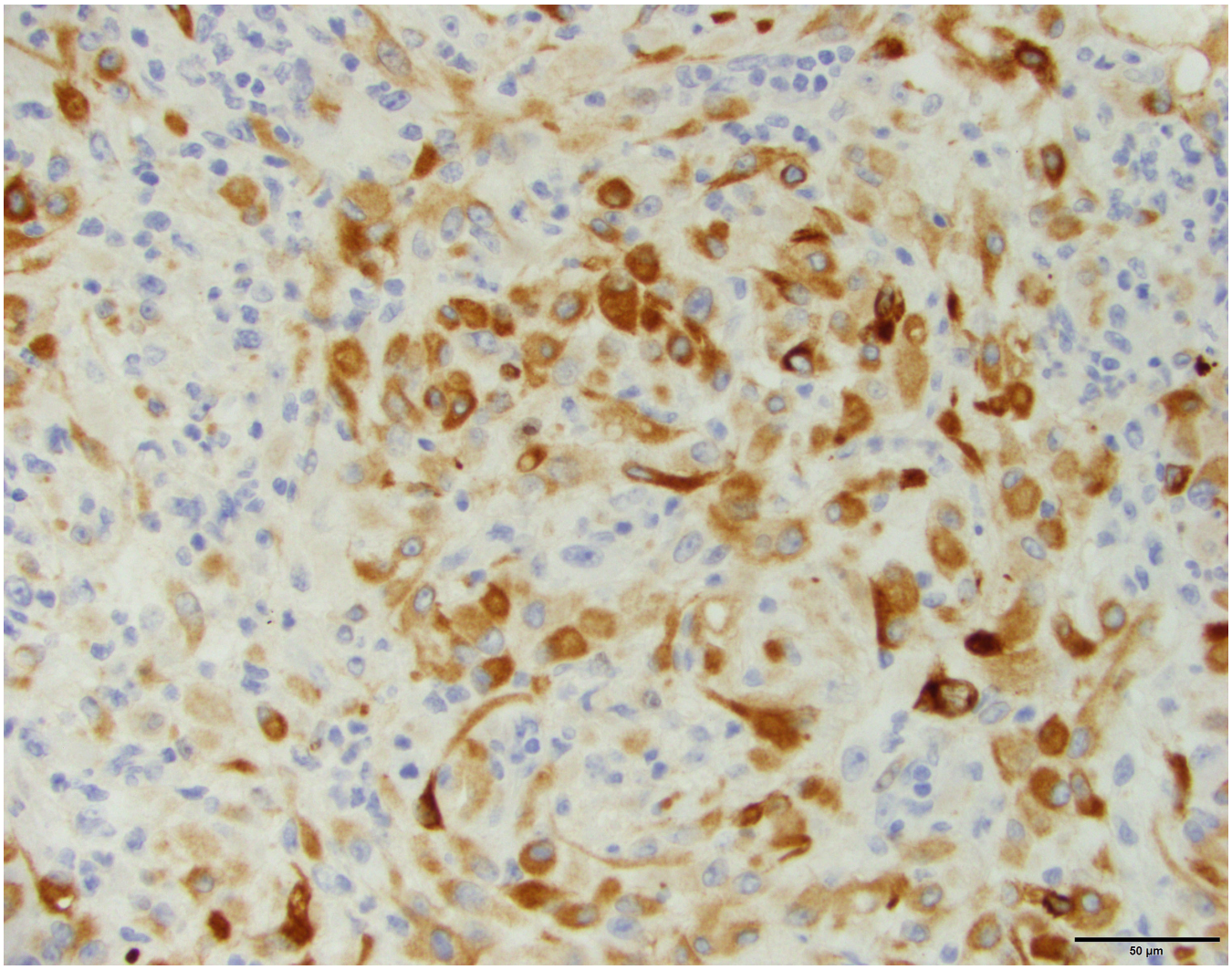

Tumor 1, vimentin stain shows that the tumor cells are strongly positive.

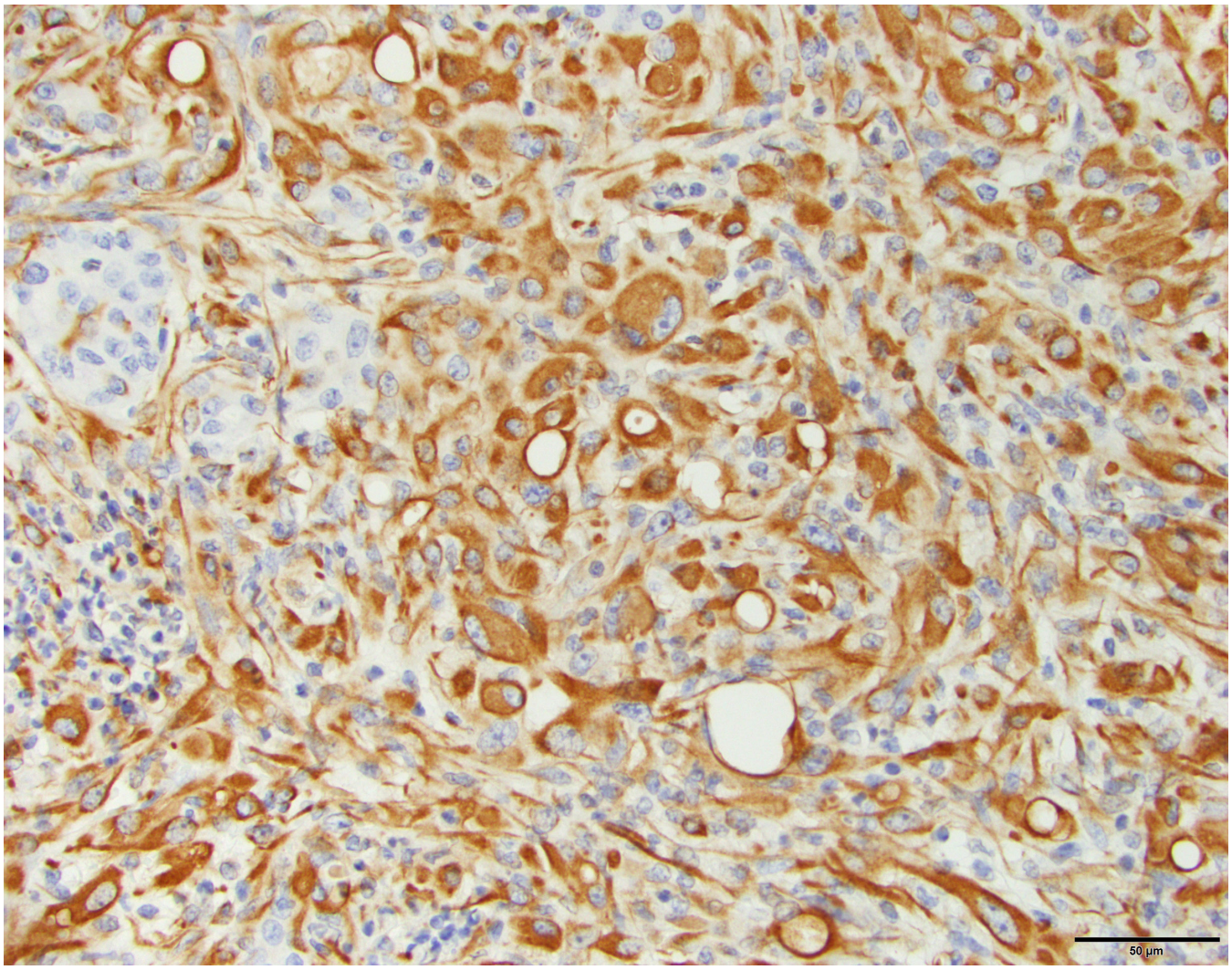

Tumor 1, Iba-1 stain shows that tumor cells are immunonegative.

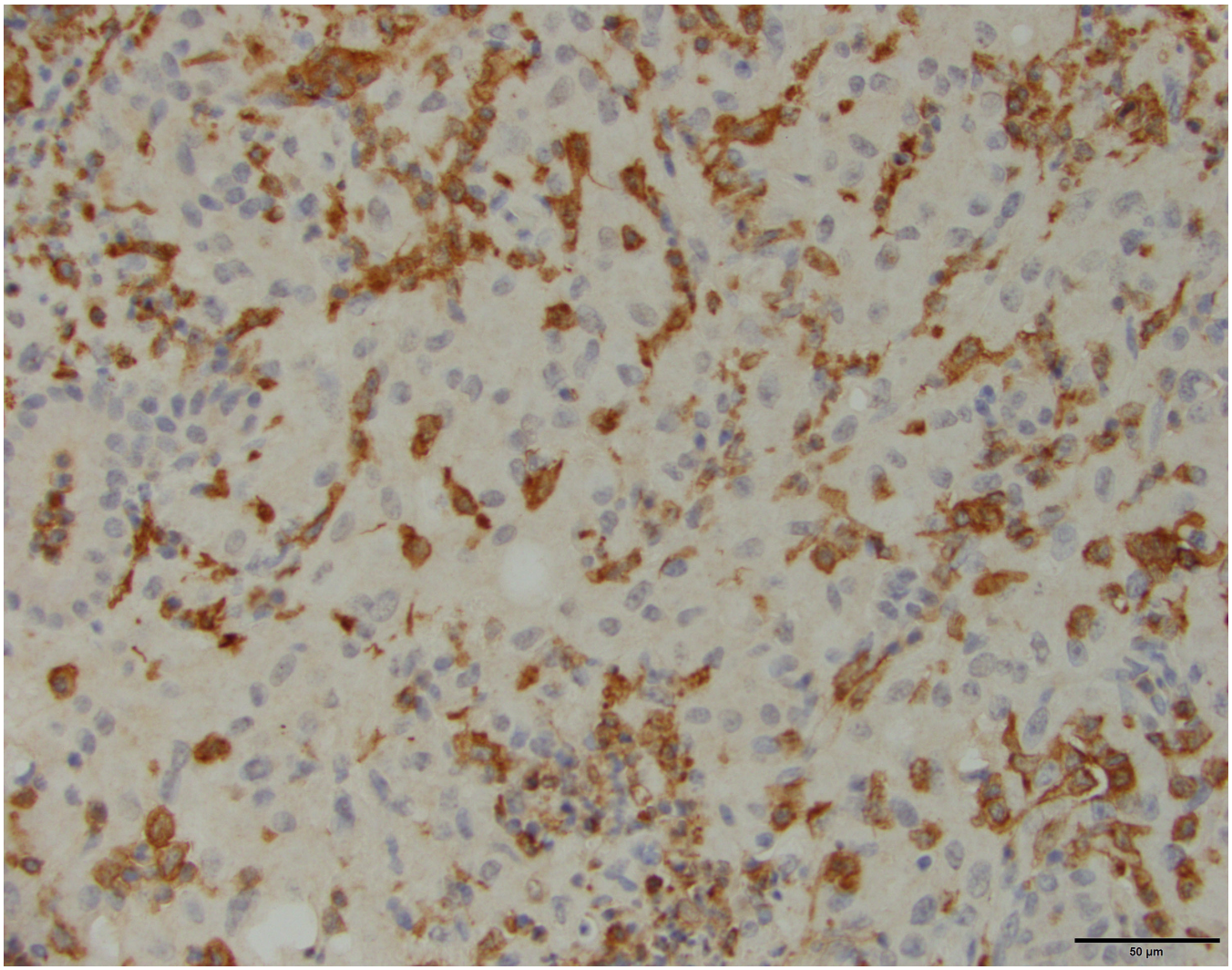

Tumor 1, Arginase stain shows that tumors cells are immunonegative, supporting a loss of hepatic differentiation.

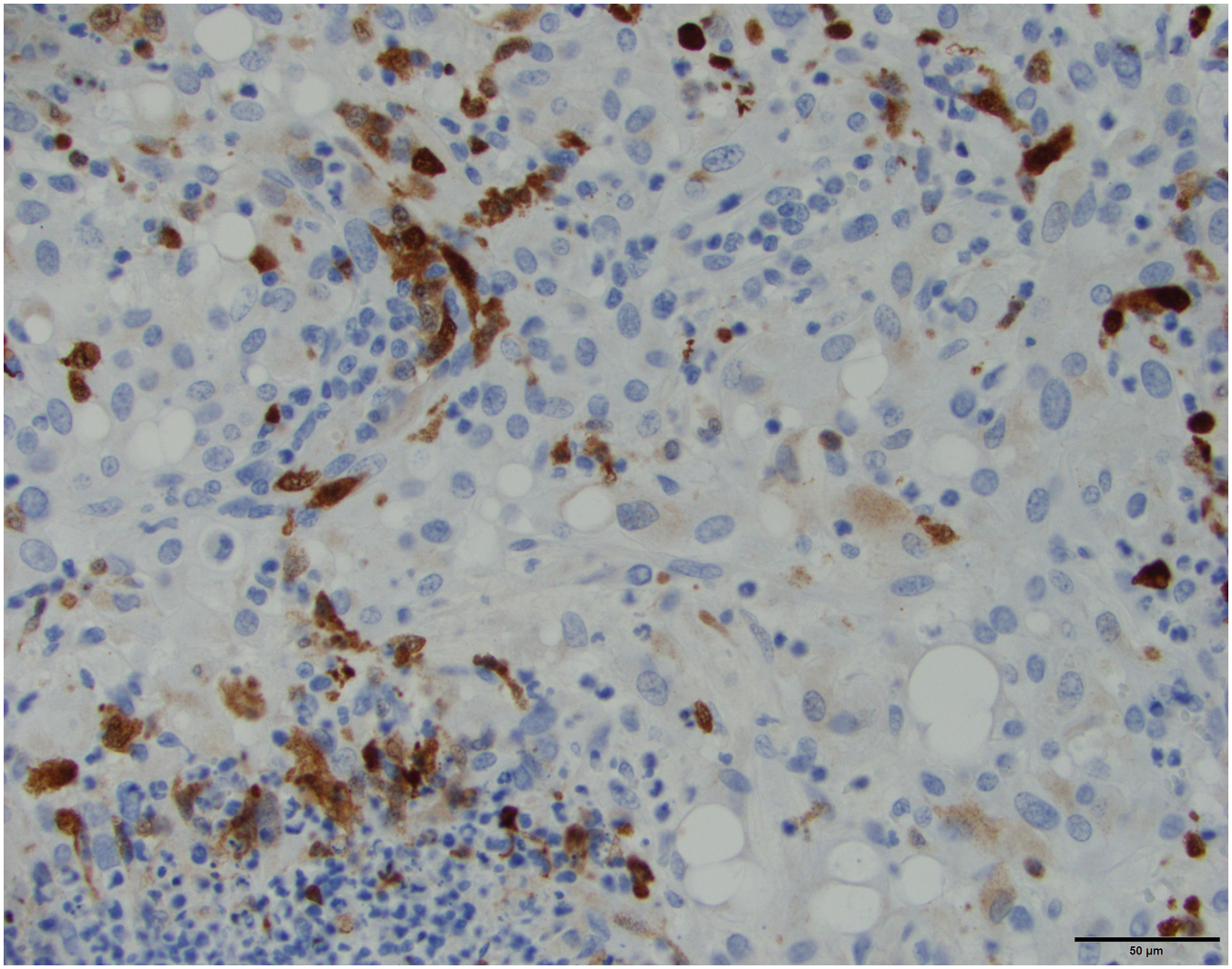

Tumor 2: Epithelioid cell predominant

H&E

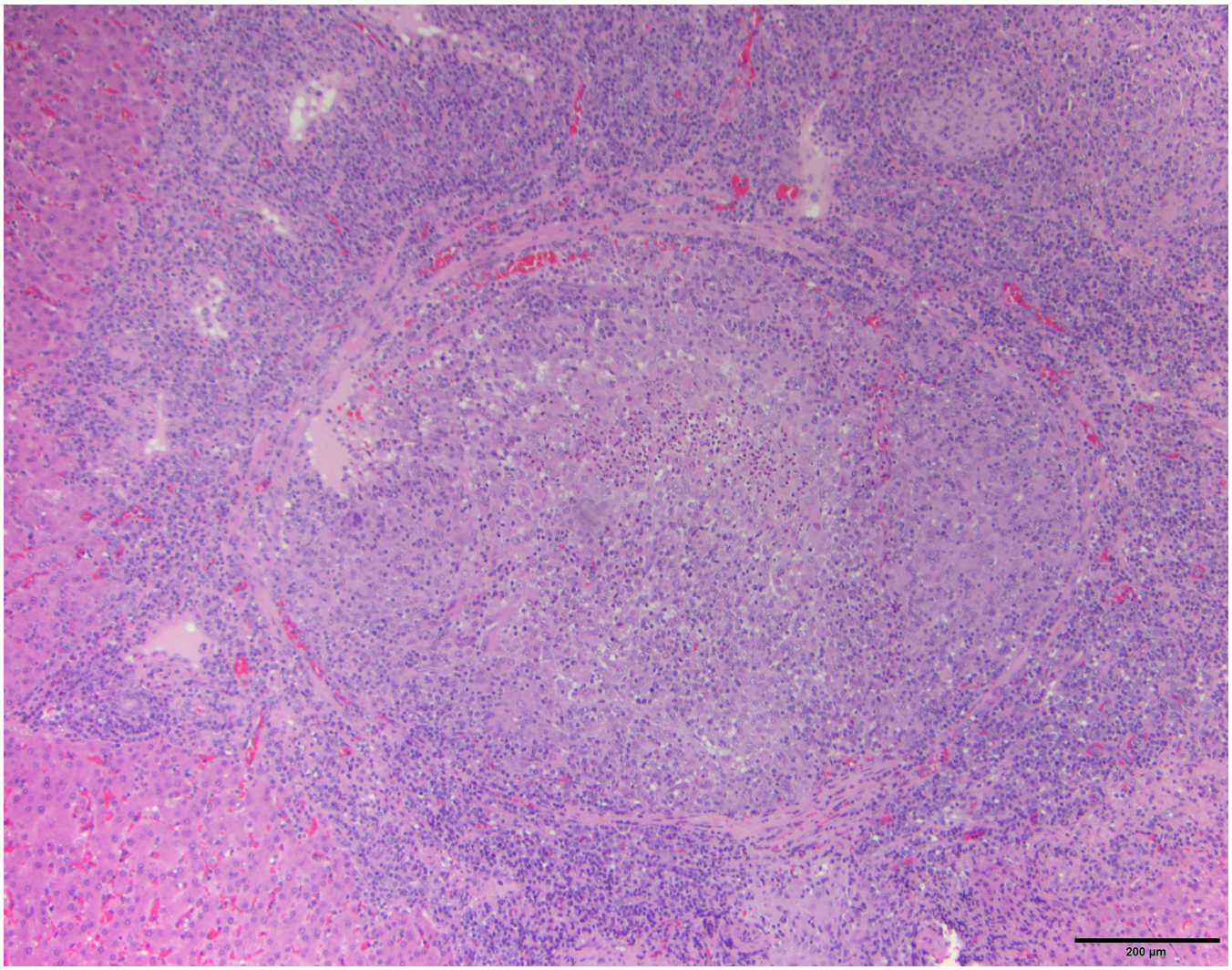

Tumor 2, vimentin

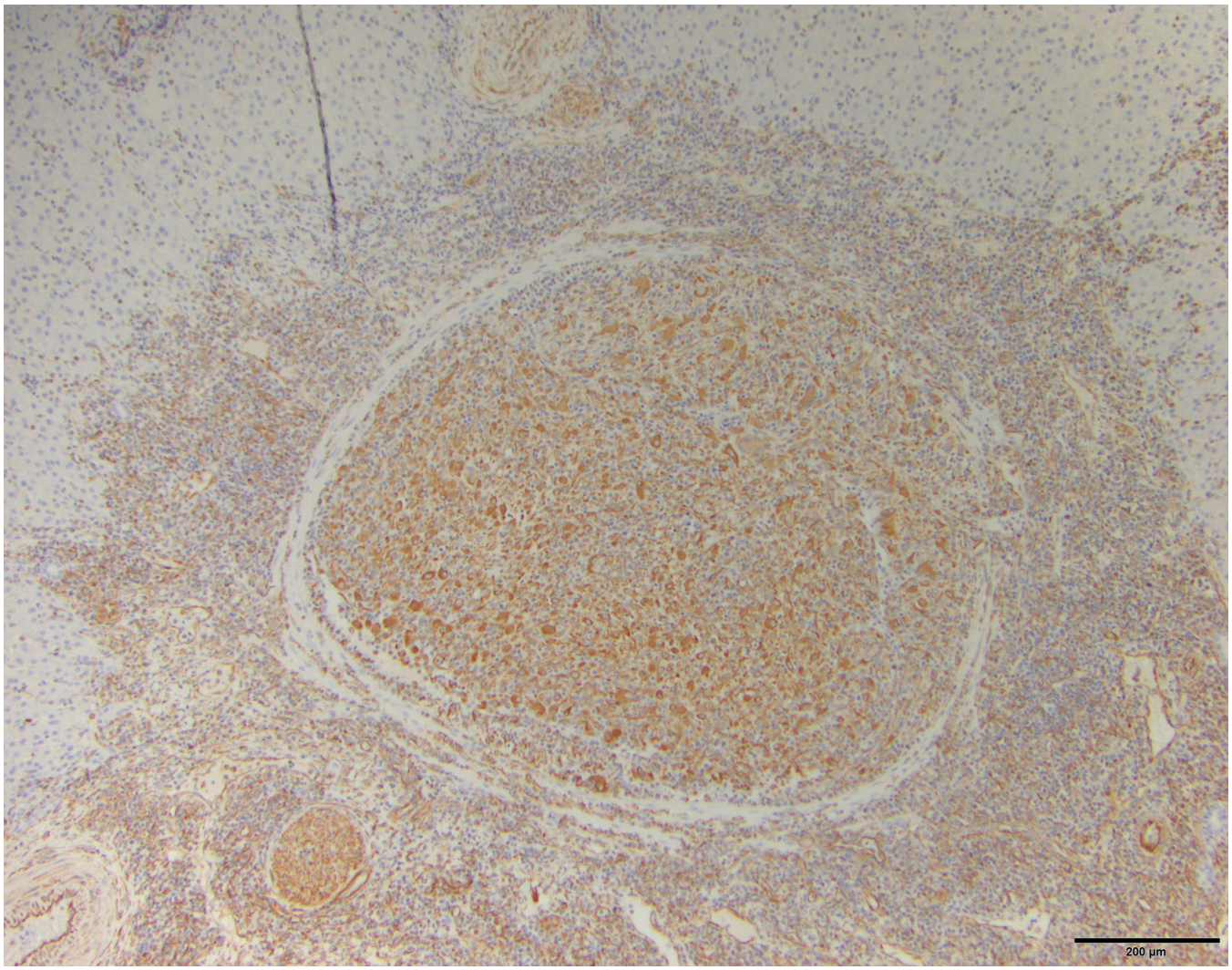

Tumor 2, CD31 staining highlights robust tumor-associated angiogenesis within the stroma.

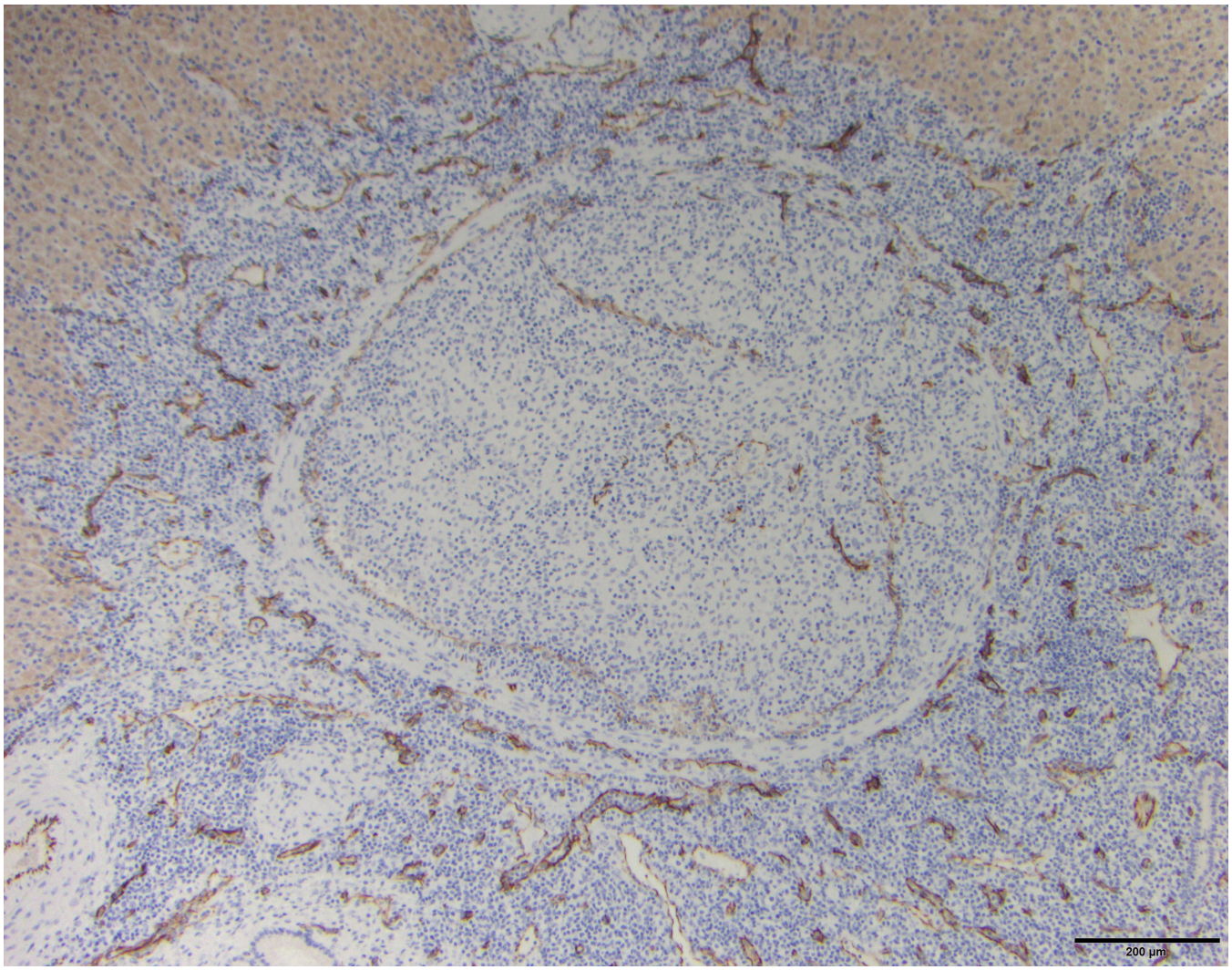

Tumor 3: Epithelioid cell predominant

H&E (arrows pointing to frequent mitotic figures)

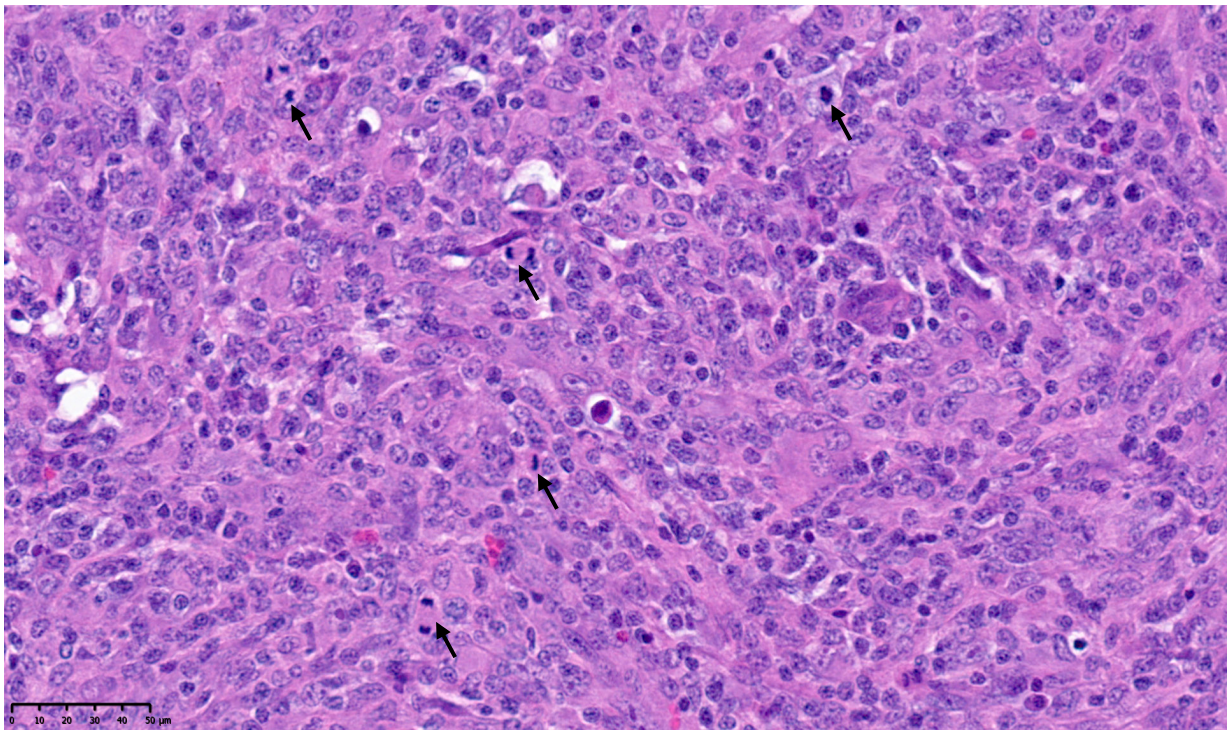

Tumor 4: Spindle cell predominant

H&E

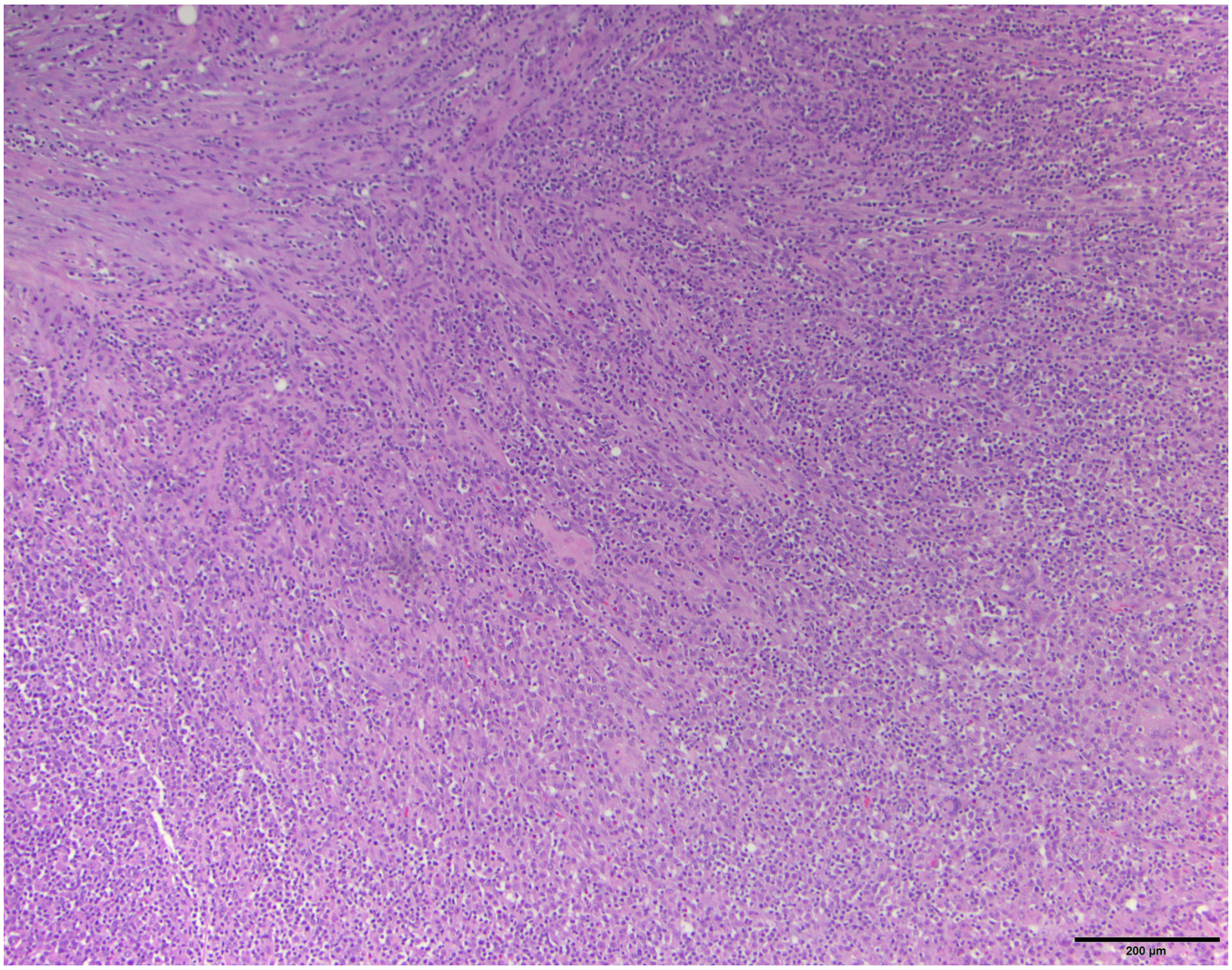

Tumor 4, H&E

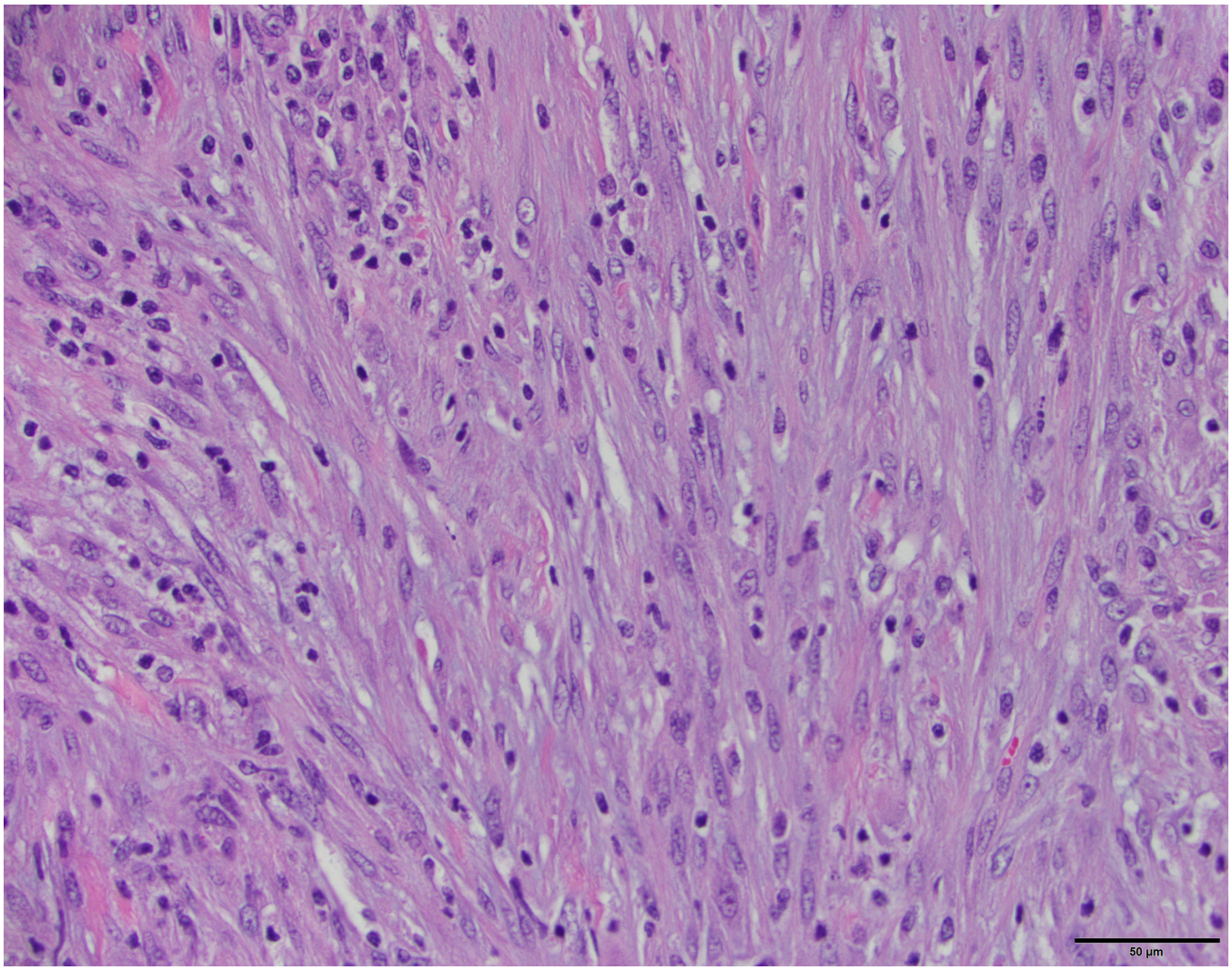

Tumor 4, cytokeratin AE1/AE3

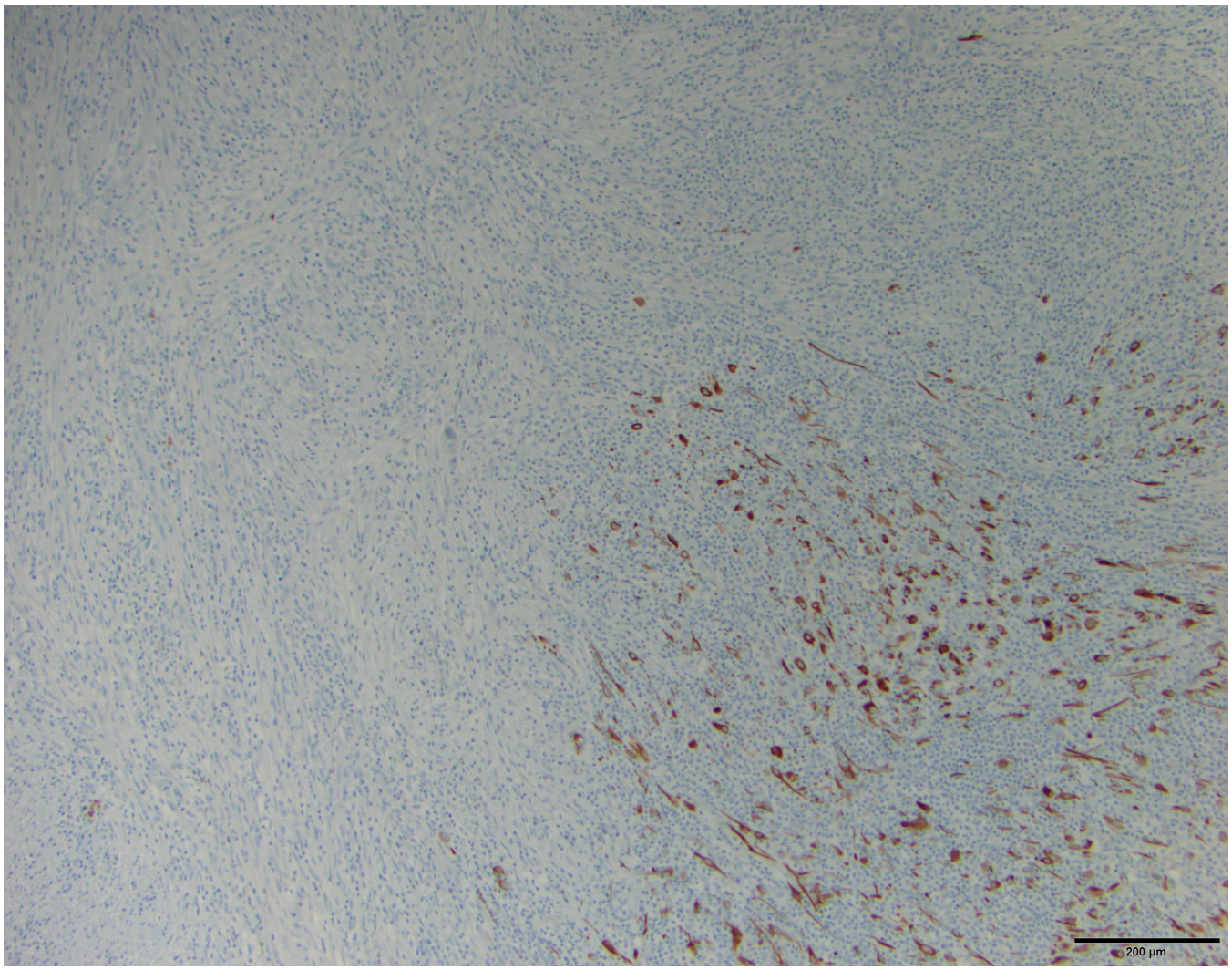

Tumor 4, cytokeratin AE1/AE3

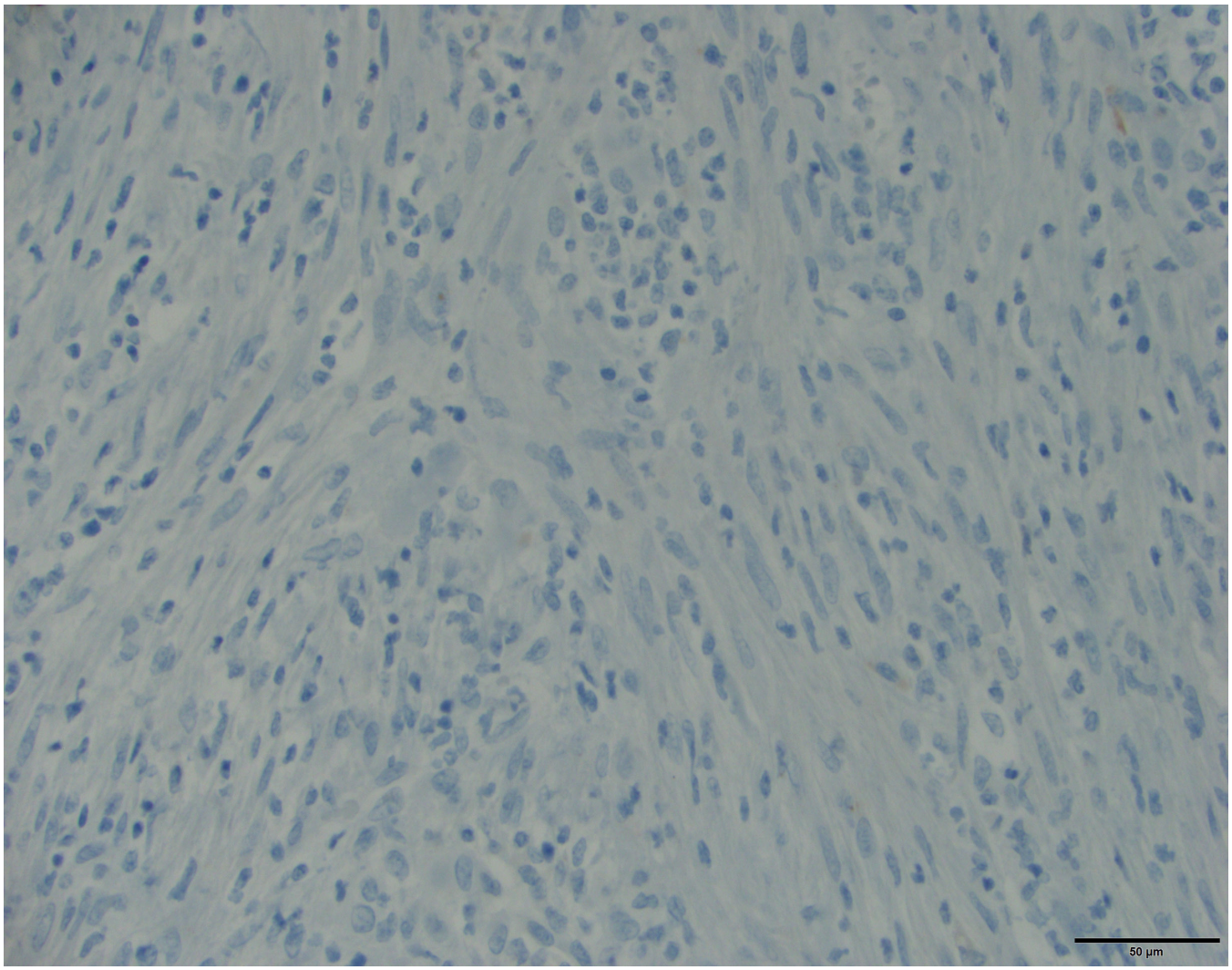

Tumor 4, vimentin

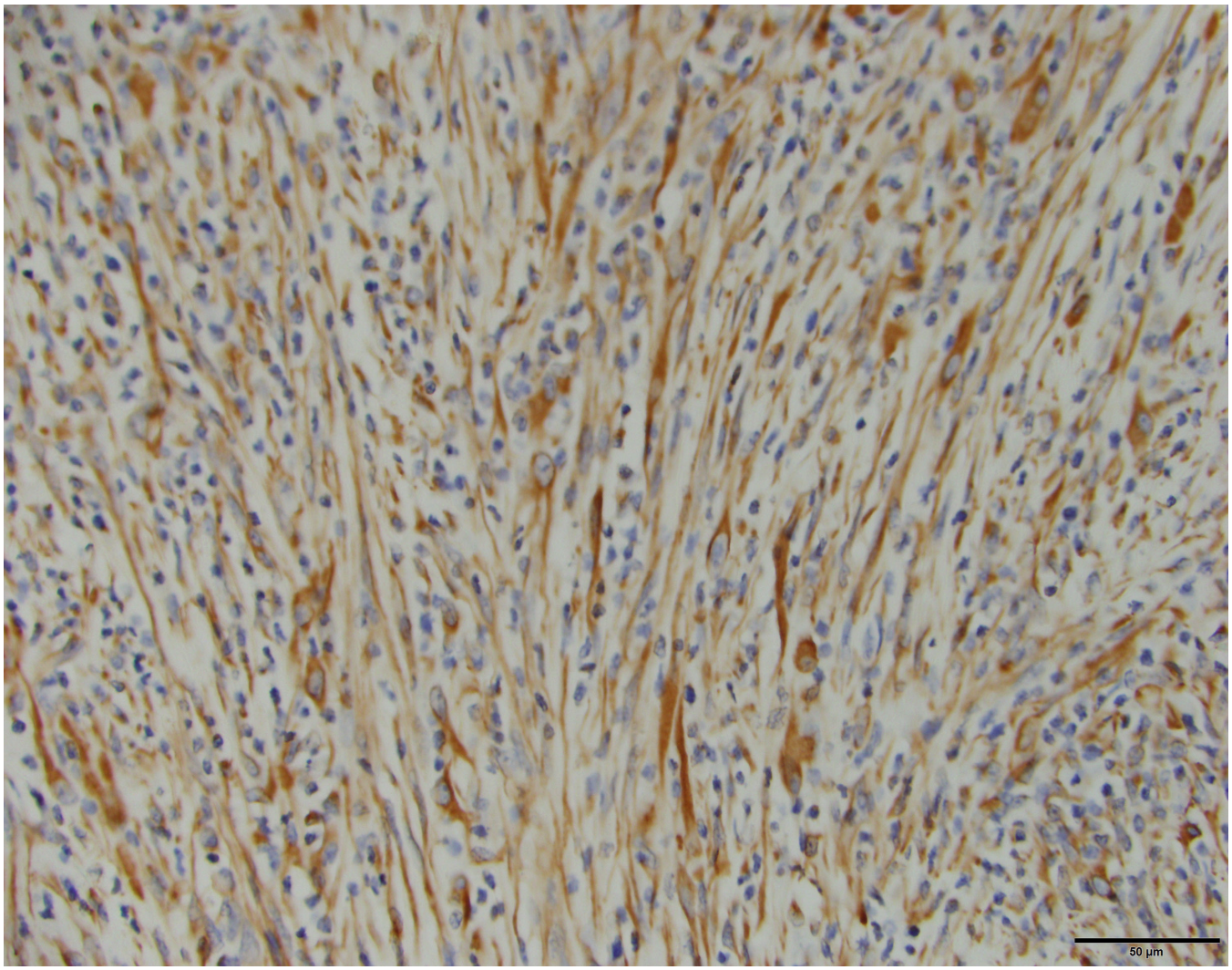

Lung metastasis

H&E

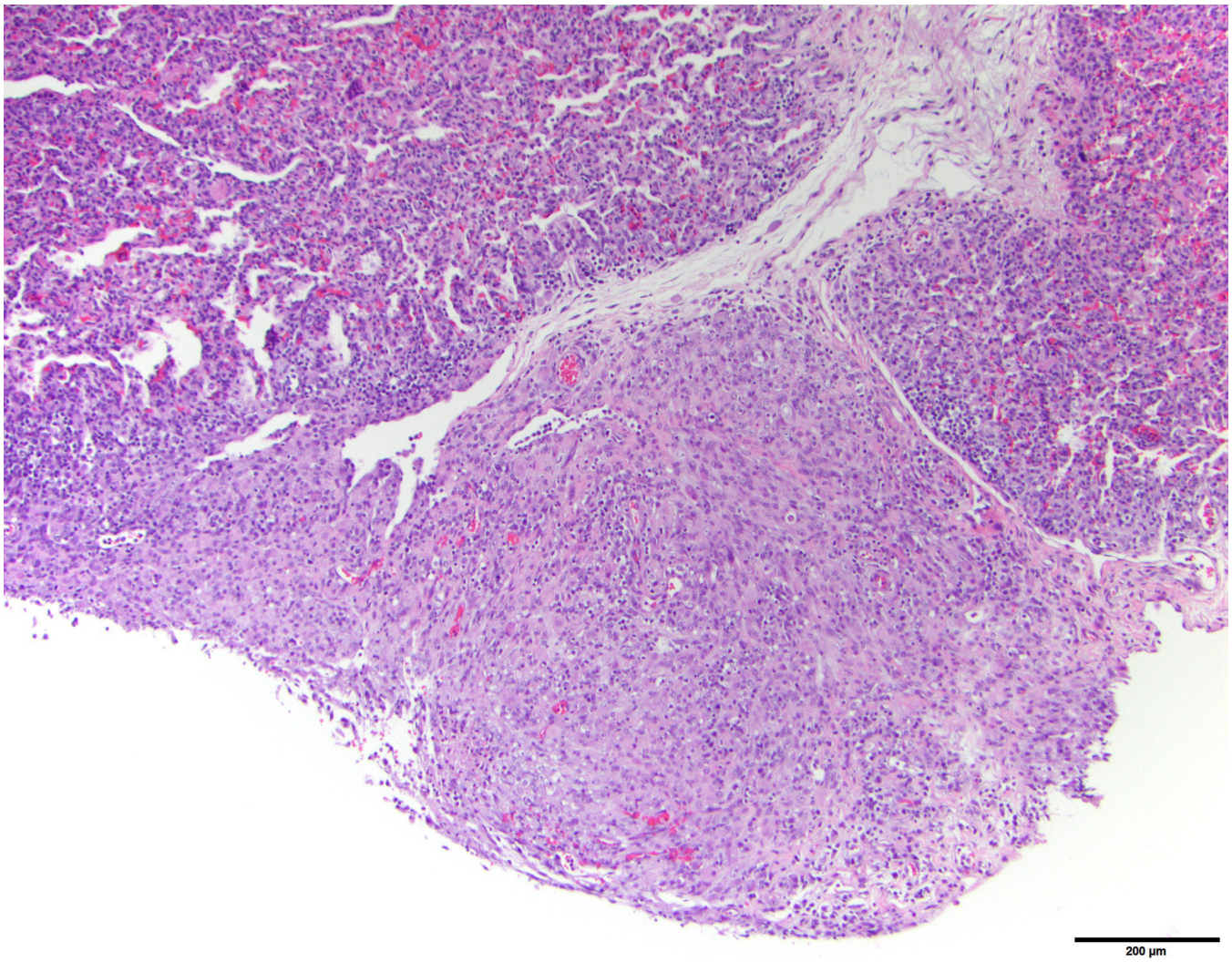

Lymph node metastasis

H&E

